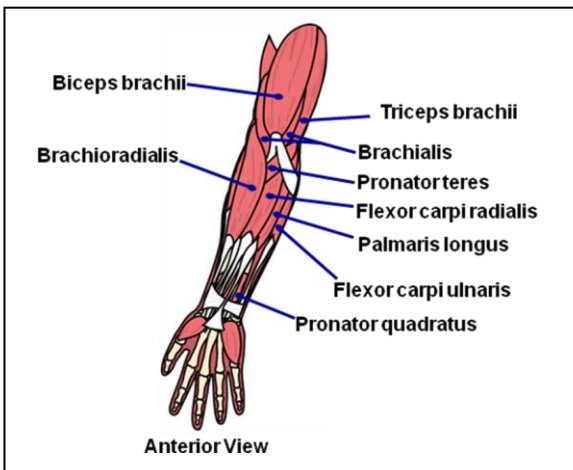


09: Axial and Appendicular Musculature

Key Terms

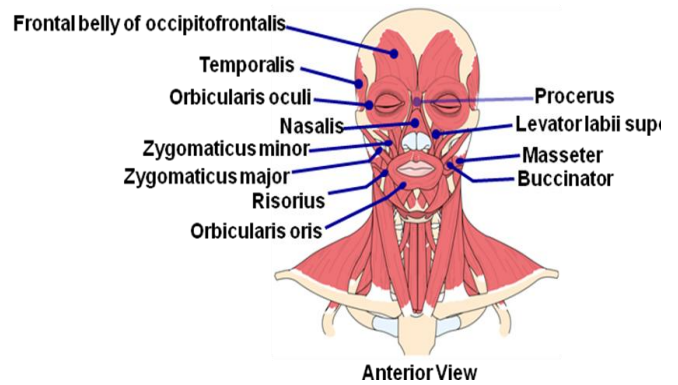
- **Axial Muscles:** the muscles of the pectoral and pelvic girdles, as well as the muscles of the upper and lower extremities, will be covered first.
- **Appendicular Muscles:** the muscles of the head and neck, vertebral column, and the muscles of the perineum and pelvic region.
- **Muscles that Move the Hand:** (1) Muscles that act at the elbow, (2) pronators and supinators, and (3) muscles that act at the wrist.
- **Quadriceps Muscles:** The muscles that extend the knee are the rectus femoris, vastus intermedius, vastus lateralis, and vastus medialis. These muscles form the quadriceps muscles. These muscles cover the anterior and lateral aspects of the femur. These are powerful extensor muscles of the knee, which are attached to the patella through the quadriceps tendon.
- **Fascia:** Fascia is a fibrous layer that permeates different regions of the body. This fibrous sheet that courses through the arms and legs separates tissue into compartments. The fascia in the thigh forms the following compartments: (1) anterior compartment, (2) medial compartment, and (3) posterior compartment.
- **Extra-ocular Muscles:** There are six extra-ocular muscles that position the eye, and are located on the surface of the orbit. The extra-ocular muscles are the: medial rectus, lateral rectus, inferior rectus, superior rectus, inferior oblique and the superior oblique muscles.
- **Mastication:** To masticate, or chew your food, the mandible and temporomandibular joint must be moved. The muscles of mastication that perform these movements are the: masseter, temporalis, medial pterygoid, and the lateral pterygoid muscle.
- **Muscles of the Tongue:** All the muscles of the tongue end in the word glossus, which is the root word for tongue. These muscles position the tongue for chewing, drinking, swallowing and speech production.
- **Muscles of the Perineum and Pelvic Diaphragm:** The muscles of the perineum and the pelvic diaphragm function to (1) support the organs of the pelvic cavity, (2) control the movements of material through the urethra and the anus, and (3) flex the joints of the sacrum and coccyx.

Muscles that Move the Hand and Forearm

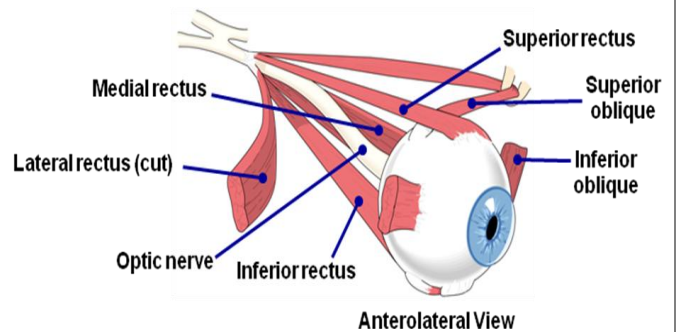


The muscles that move the hand can be organized by groups: (1) Muscles that act at the elbow, (2) pronators and supinators, and (3) muscles that act at the wrist.

Head and Neck Muscles

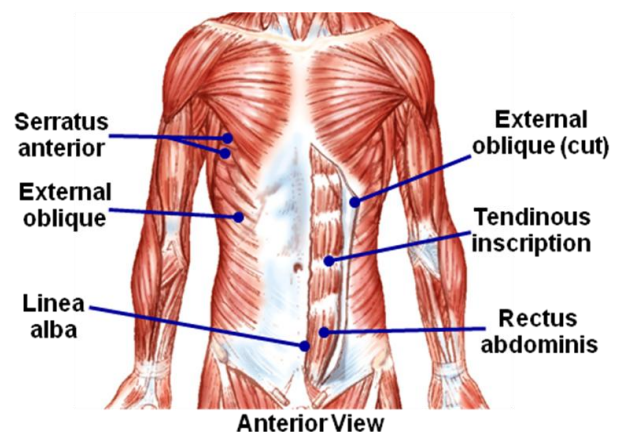


Extra-Ocular Muscles



There are six extra-ocular muscles that position the eye, and are located on the surface of the orbit. The extra-ocular muscles are the: medial rectus, lateral rectus, inferior rectus, superior rectus, inferior oblique and the superior oblique muscles.

Oblique and Rectus Musculature



How to Use This Cheat Sheet: These are the keys related this topic. Try to read through it carefully twice then rewrite it out on a blank sheet of paper. Review it again before the exams.